



Case Study

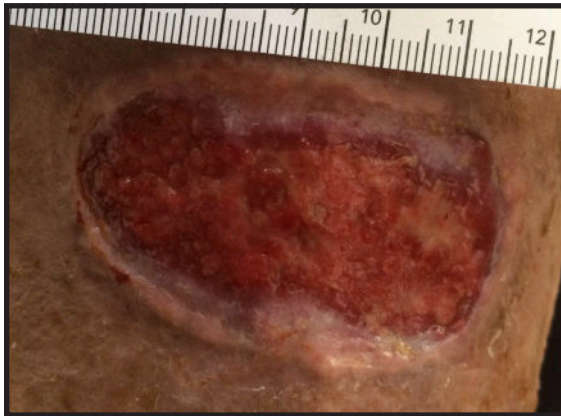Treatment of a Traumatic Shin Wound with CDO Therapy

Dr. Rena D. Pine

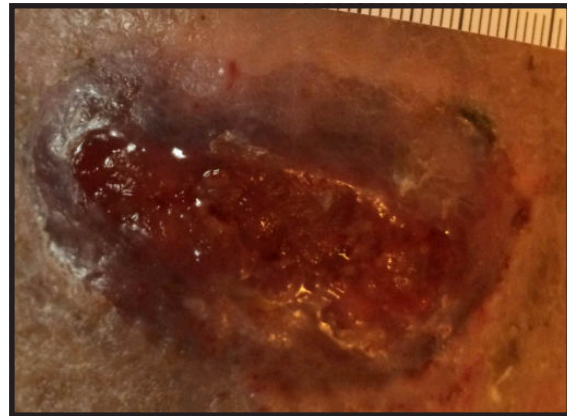
Wound Nurse: Kathy Brown, RN, MN, CWOCN, Rochester, New York

Patient:	72 year old female with a traumatic wound on left shin
Wound Age:	180 days
Medical History:	Altered mental/mobility, dementia, aphasia, anxiety, tremors, HTN, osteoporosis, A Fib, edema
Previous Therapy:	Moist wound therapy, TenderWet®, Aquacel®, Santyl®
Treatment:	OxyGeni® set at 5-8 ml/hr using an OxySpur® Diffusion Dressing
Days on Service:	77 days
Outcome:	Wound healed. High patient and facility satisfaction.

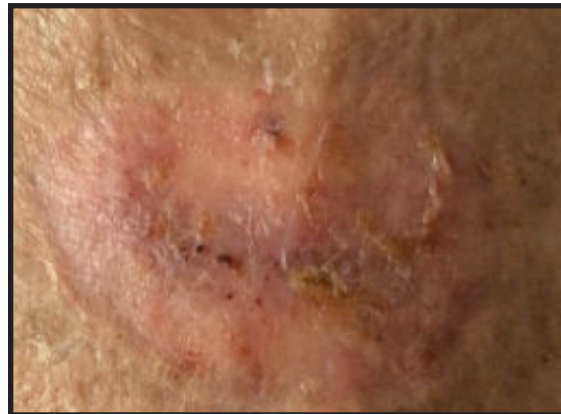
Day 6 of CDO



Day 21 of CDO



Day 56 of CDO



Patient was left on CDO therapy until day 77 to ensure healing